

# An Implementation Guide to C-View™ Software That Minimizes Dose and Recalls while Maximizing Physician Confidence

Sally Deborah Herschorn, MD

Medical Director, Breast Imaging, The University of Vermont Medical Center

## Introduction

The University of Vermont Medical Center was one of the first facilities to implement Hologic's Genius™ 3D Mammography™ exam in Vermont, installing one Hologic Selenia® Dimensions® system in 2012, and eventually expanding to seven total units across our three campuses. Despite the increase in interpretation time, our radiologists embraced 3D™ breast imaging for its ability to detect cancers not seen on 2D images and for its ability to reduce callbacks. By 2015, about 80-85% of our screening mammograms were tomosynthesis screens, using the standard combo mode of 2D + 3D™. We are now at 92-95% tomosynthesis screens; all performed with Hologic's C-View™ software.

When we implemented 3D™ imaging in 2012, Hologic's C-View software was not approved in the U.S. for use. Although we felt comfortable that the radiation dose with 2D + 3D™ was acceptable, we did feel it was necessary to notify patients that there was increased dose. Some patients did express concern about the dose and declined a 3D™ exam because of their fear of radiation. In addition, in 2D + 3D™ combo exams, we noticed the 2D exam was often impaired by motion, usually due to the slightly longer exam time in compression. We added Hologic's C-View software so we could provide patients with the benefits of the 3D™ technology without significant additional radiation and also with the hope of obtaining sharper images with less motion.

Our goal was 100% 3D™ imaging. Over time, other imaging facilities in our area added 3D Mammography™ and the newer units came with C-View software. As they dropped the 2D exam, these facilities were able to provide 3D Mammography™ exams with a lower radiation dose, leaving our facilities at a disadvantage in terms of dose.

This paper discusses our approach to implementing C-View images on all Hologic 3D Mammography™ systems at the University of Vermont Medical Center and reviews some well known artifacts seen with C-View software. We implemented in phases in order to maintain our workflow and provide our staff of 22 technologists and six radiologists time to gain confidence in the C-View images. Within three months of

implementing the software, we were able to eliminate the 2D scan, establish 3D™ + C-View imaging as our standard of care, and reduce the radiation dose to patients.

## C-View Images Replace 2D Scans, Lowering the Radiation Dose

The C-View software automatically generates synthesized 2D images from the tomosynthesis data without the need for a 2D scan. The literature has consistently shown Hologic 3D™ + C-View synthesized 2D, to be superior to FFDM alone<sup>2-5</sup> and does not involve an additional radiation dose beyond that of the tomosynthesis scan, which is approximately 45% less than the 2D + 3D™ screening exam.<sup>2</sup>

Two papers, in particular, provide the clinical evidence that C-View software is equivalent in diagnostic accuracy to 2D + 3D™; *Two-View Digital Breast Tomosynthesis Screening with Synthetically Reconstructed Projection Images: Comparison with Digital Breast Tomosynthesis with Full-Field Digital Mammographic Images*<sup>3</sup> and, *Comparison of Two-dimensional Synthesized Mammograms versus Original Digital Mammograms Alone and in Combination with Tomosynthesis Images*.<sup>4</sup>

It is important to note the C-View image is not a diagnostic image on its own, and is designed to provide a roadmap to the tomosynthesis slices. Clinical decisions are based on review of the tomosynthesis slices. Nevertheless, the C-View image is important to have for comparison with prior studies.

## Implementation

The timing of our implementation of C-View software was dependent on the availability of computer-aided detection (CAD) and our budgeting process. We had purchased our Selenia Dimensions systems prior to the availability of C-View software; so, we required a software upgrade for each of our six Selenia Dimensions systems. As well, early on, CAD was not available for C-View images and our radiologists did not feel comfortable without CAD for detection of calcifications.

Our implementation goals were to transition quickly without disrupting our workflows or increasing false-positive callbacks. There was definitely a learning curve with interpretation of the C-View images. However, this learning curve is not that dissimilar from the one we experienced transitioning from one digital mammography vendor to another. Our process for successful implementation included:

- Involving the entire section leadership in the planning process
- Requiring online training for radiologists and onsite training for technologists
- Dropping the 2D for diagnostic exams first, followed by screens
- Requiring double reading of borderline callback cases for the first 3 months

## Planning

We began by bringing together our leadership team, including the division chief, the lead technologist, and the physicist to identify potential issues. These meetings were key to ensuring everyone was working towards the same goals. Our physicist initially had concerns about the C-View image quality but further investigation taught us that this is not a substitute for a 2D image, but a roadmap for interpreting a 3D™ image, and as such, does not need to have the same diagnostic quality. We invested many, many hours and revised the implementation plan numerous times. But, our attention to detail helped the process go smoothly.

## Training

The next step was to train our staff of 22 technologists and six radiologists on C-View images, so they were comfortable and confident with the new software. We began by introducing details of the implementation plan in staff meetings and then identified online tutorials and application training specific to technologists and radiologists.

We provided our staff with the following online tutorials and asked them to complete the tutorials within a two-week timeframe, after which time we implemented C-View software on our first system.

The tutorials were developed by Hologic and Applied Radiology, and provided three hours of CME.

Two key online tutorials were:

### **1. ICPME - State of the Art Mammography: The role of full field digital imaging, generated 2D images, and digital breast tomosynthesis**

- Dr. Linda R.N. Greer, Medical Director, John C. Lincoln Breast Health and Research Center, Phoenix, AZ, originally presented this webinar on May 6, 2014. Physicians earn 1.0 AMA PRA Category 1 Credit and/or 1.0 ARRT Category A Credit.

### **2. Applied Radiology – Tomosynthesis & Synthesized 2D Imaging Webinar Series**

- Tomosynthesis & Synthesized 2D Imaging Part I – Originally held October 1, 2013
- Tomosynthesis & Synthesized 2D Imaging Part II – Originally held October 8, 2013
- Dr. Elizabeth A. Rafferty, Massachusetts General Hospital and Dr. Aron J. Belfer of CDB-Premium in Brazil presented these seminars in October 2013. Physicians earn 1.0 AMA PRA Category 1 Credit and 1.0 ARRT Category A Credit.

## Transitioning: Building Confidence in Reading C-View Images

We opted to implement C-View imaging in steps, adding C-View software to each of the six Selenia Dimensions systems sequentially. It takes a few days to upgrade each system; and, we didn't want to interfere with workflows and patient access, particularly in the diagnostic center.

We decided to drop the 2D scan on post clip exams as soon as C-View software was available in our diagnostic center. Post clip exams are mainly used to assess clip/lesion concordance and not used much for diagnosis. This allowed us to lower the radiation dose immediately for this patient population. We dropped the 2D scan for diagnostic mammograms next, then for screening exams.

To accelerate radiologists' confidence in the C-View image, we recommend:

- Displaying the C-View image on the SecurView workstation as the first image in the display protocol, with the 2D image behind the C-View image.
- Educating radiologists about the known artifacts that are present with C-View software.

One of our major concerns about eliminating the 2D scan was the potential for increased recalls associated with "pseudo-calcifications". By design, C-View images look different than the conventional FFDM image; they have more contrast, which makes calcifications stand out more than on 2D images and may make it look like there are calcifications, when in reality there are only summated dense fibers within the breast. This is because the C-View image combines and accentuates important breast tissue features, such as bright spots and radiating lines, in order to facilitate navigation through the tomosynthesis slices.

## Reading Both 2D and C-View Images

During the first two months of our transition we read both 2D and C-View images for all screening exams. It definitely takes more time to read both images, clicking back and forth to display the two sets of images. However, as I noted previously, the C-View image is different than the 2D image; and, as with any new technology, it is important to provide radiologists with time to become familiar with the images.

Initially, we displayed the 2D images first, then C-View images, but we found that after reviewing the 2D image radiologists didn't always look at the C-View image. So we reversed our display protocol to present the C-View image, prior to the 2D images. This was an important change, which accelerated our confidence in the C-View image.

## Eliminating 2D for Diagnostic Exams

When the radiologists felt comfortable reading the dual 2D and C-View images, we decided to drop the 2D for diagnostic exams. We were aware that many facilities chose to drop the 2D for screening first, but we were concerned we would see an increase in false-positive callbacks related to structures that appeared to be calcifications on C-View image but were actually not calcifications. We felt that with diagnostic exams, the radiologist is reviewing the image while the patient is still in the department and if a radiologist was concerned that there might be questionable calcifications on the C-view image, he or she could ask for a 2D or a spot magnification view to be done while the patient was still in the department; thus avoiding a recall. We anticipated seeing a number of extra 2D images done for radiologists who just wanted that reassurance. However, since many diagnostic exams already require a number of spot magnifications, this wasn't an issue; and, as a result, we found very few cases in which the radiologist requested additional 2D images to supplement the C-View images.

Dropping the 2D with diagnostics was a great way to help our radiologists become familiar with the C-View images and gain confidence. After only three weeks, the radiologists felt ready to use C-View images on all exams including screenings, and completely do away with 2D.

In another effort to reduce the callback rate during the first three months after we dropped the 2D views, we required a second read whenever a radiologist wanted to recall a patient because of calcifications that weren't completely obvious. The second reader often was able to be more confident that the bright spots in question were not real calcifications. This helped avoid a lot

of unnecessary recalls during the transition period when our radiologists were getting used to the C-View images. It really is a process of training your eye, and gaining experience with the images.

## Recognizing Known Artifacts

During the initial implementation period for C-View software, when we were doing both 2D and C-View images and working to get accustomed to the C-View image, we were seeing an artifact on the back of the C-View image, a white bar less than a millimeter thick. We also noticed differences in the skin line on some images.

Additionally, we created a variety of teaching cases to familiarize radiologists with the difference between the C-View and 2D images.

Understanding C-View artifacts is an important part of the implementation process. The following are examples of known differences between 2D and C-View images.

### Skin Line

**Bright band under skin line in roll-off region on C-View image**  
(see Figure 1)

In certain instances, a bright white band appears on C-View images just under the skin line as shown in the image below. Skin line information for C-View images is sourced from

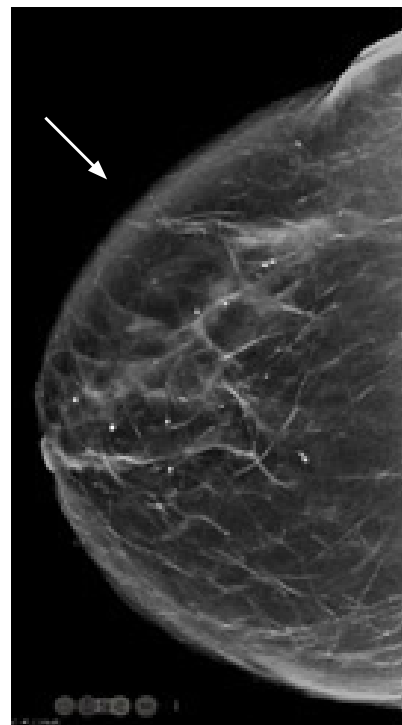


Figure 1. Skin Line

tomosynthesis slices. In the roll-off region of the breast, the edge of the breast changes its location when projected on a synthesized image as you scroll through the tomosynthesis slices. As a result, in this roll-off region, a bright band occasionally is generated on C-View images. Images are more likely to be susceptible to this due to inadequate compression, which may lead to a larger roll-off region. However, this bright band still enables you to visualize the tissue in the roll-off region with sufficient contrast and should not affect the diagnosis, which is performed primarily using tomosynthesis slices.

**Dark regions on C-View image near skin folds** (see Figure 2)

Large skin folds lead to sudden transitions in pixel values on an image, which tend to result in dark regions, or shadows, near the line of transition in tomosynthesis reconstructed slices.

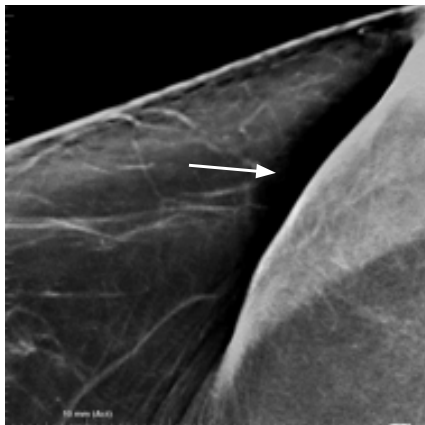

Figure 2. Dark regions near skin folds

These shadows are a side effect of image processing filters, which, in fact, provide the most optimal details in the rest of the breast tissue, and offer the advantage of enhanced contrast for a diagnostic quality image. C-View images typically retain the salient information from the tomosynthesis slices and therefore the dark regions near skinfolds tend to be even more prominent in the C-View images. Hologic advises users to scroll through the tomosynthesis slices carefully to review all tissue. However, better positioning to avoid large skinfolds will overcome this issue.

**Burned skin line** (see Figure 3)

Occasionally C-View images exhibit “burned skin line” which is due to rare instances of missing skin line in tomosynthesis slices. The appearance of burnt tissue is typically only at the edges of the breasts and happens due to saturation of the detector at a few pixels close to the edge of the breast where the skin tissue ends. Typically, large size breasts suffer from this because the larger thickness requires more penetration resulting in a higher chance of detector saturation. In either case, there is no loss of breast tissue; pixels that may be lost in saturation are at the only very edge of the skin.

Arrows in the image on the left below show the skin line on the C-View image. The image on the right below is the corresponding region from the tomosynthesis slice shown at extreme window and level to indicate the regions of saturation.

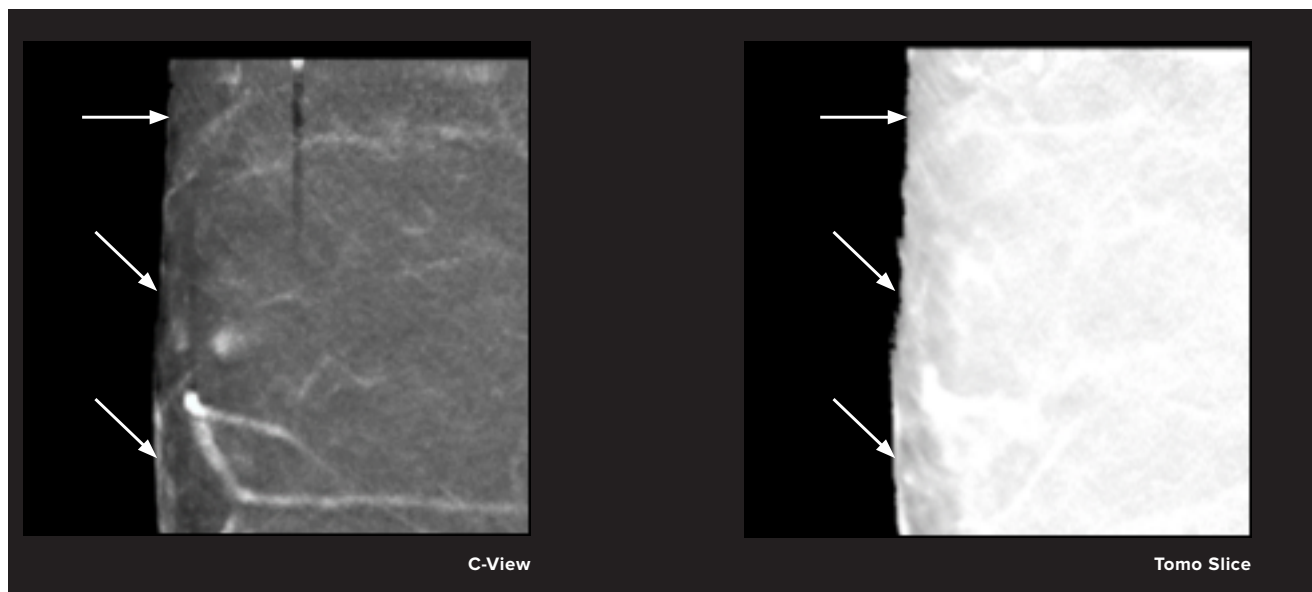
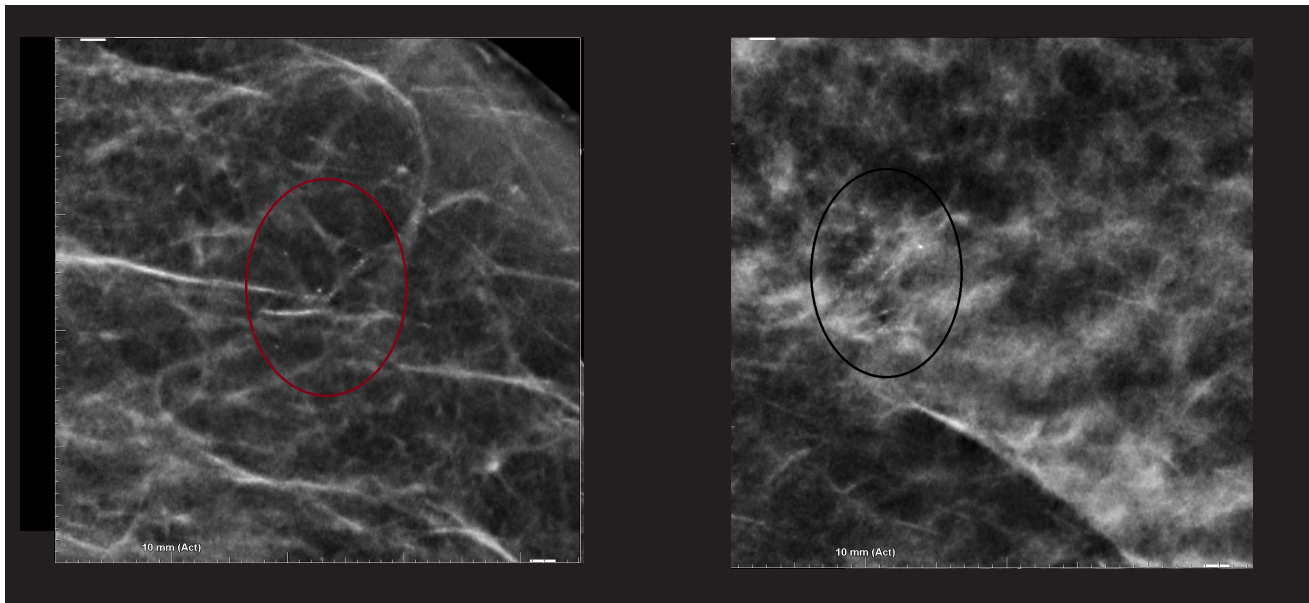


Figure 3. Burned skin line



**Figure 4. Calcifications: False positive calcifications**

## Calcifications

### Bright spots and false positive calcifications (See Figure 4)

C-View software increases the contrast of bright spots to facilitate easy detection of calcification clusters while navigating tomosynthesis slices. Sometimes, bright spots may be statistical fluctuations rather than calcifications. C-View imaging enhances these fluctuations to the point that they may appear as calcifications; the algorithm's contrast enhancement of real calcifications assists radiologists in spotting subtle clusters easily and therefore the occasional enhancement of noise is a price worth paying, in our opinion. Typically, C-View images are used for initial detection of calcifications and the C-View image is reviewed along with the tomosynthesis images to detect whether or not calcifications are present. Once calcifications that cannot be characterized as typically benign (e.g. vascular, oil cyst, etc.) are detected, their morphology is best assessed with spot magnification views. The radiologist should refer to the tomosynthesis slices to confirm calcification clusters that may appear to be ambiguous. White arrows in the images above show examples of false-positive calcifications. If a suspicious bright spot is not present in the underlying tomosynthesis slices, it may be confidently ruled out as a true calcification.

### Pseudo-increase in calcification

Due to the increased conspicuity of calcifications with C-view images, when compared with conventional 2D images from a prior year, it may appear, in comparison with older studies, that

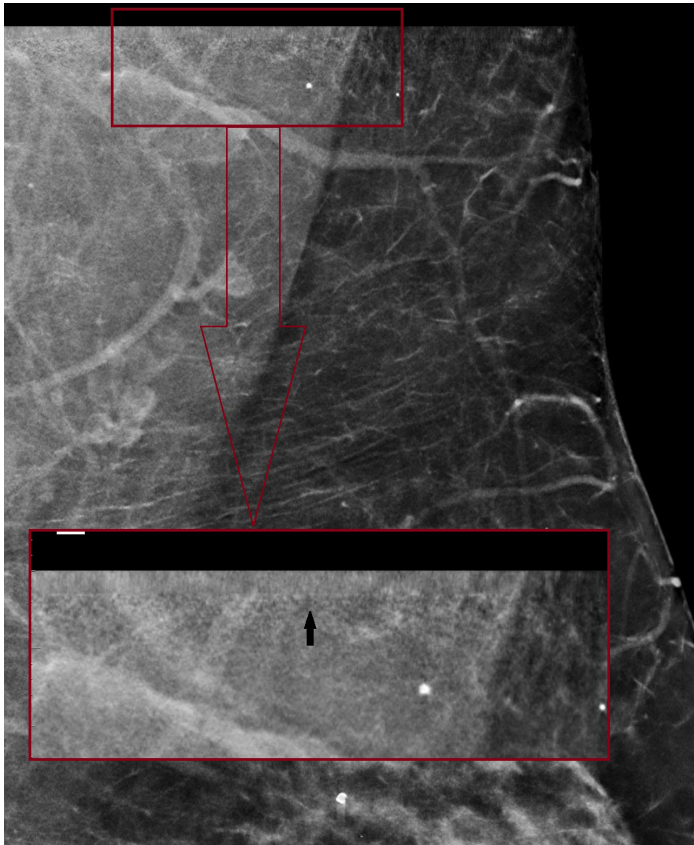
the calcifications have increased or are new; when in fact they were present previously and are unchanged. If the prior exam was a 2D + 3D™ combo, sometimes subtle calcifications may not have been visible on the most recent comparison 2D study because of motion on the 2D. However, the calcifications could be visible if you scrolled through the 3D™ data set from the prior study and then compared their appearance with the current 3D™ slice.

### False-negative amorphous calcifications

On rare occasions, certain amorphous micro-calcifications can be blurred out in tomosynthesis slices to the degree that they are not visible. This may happen due to patient motion during the acquisition of the 15 projections; these micro-calcifications have very weak signal and even a small degree of motion can blur them out. Because C-View software derives all its information from tomosynthesis slices, if calcifications are blurred out on the tomosynthesis slices, they do not appear on C-View images either. In certain instances, the C-View algorithm may not be able to locate extremely small and subtle calcifications in tomosynthesis slices, and, therefore, they may not be accentuated on C-View images. They still will appear in the C-View image, but just not with the added contrast enhancement.

### Clip artifact

It often appears that there are reconstruction artifacts, occasionally mimicking calcifications, adjacent to a clip; that are resulting from limited angle projection reconstruction



**Figure 5. Band on top of MLO images**

method. The clip may also produce a slinky artifact; which can be mitigated with clip suppression, (also known as “de-metal”) software option.

**Band on top of MLO images** (see Figure 5)

A narrow band of pixels, which looks like a horizontal blur or fuzzy area, appears mostly on the top section of MLO images (pectoral area). This may appear stronger in some images than others, especially those acquired with the large compression paddle. This effect comes from the limited angle projection acquisition of tomosynthesis, the larger the angle, the stronger the effect, as more tissue is outside the field of view of a certain number of tomosynthesis projections.

For example, the top part of the breast tissue in an MLO image does not exist in all the projection images because each projection is taken at a slightly different angle and has a slightly different capture field of view on the detector. This is more apparent on C-View software because it combines information from all tomosynthesis slices and the effects of noise can be exaggerated during the C-View image generation process. However, as it is very narrow and only affects the very top of the

axillary muscle area, it is not expected to affect diagnostic value of tomosynthesis or the C-View image.

**Workflow Efficiencies**

We experienced efficiencies in two areas:

- Our technologists no longer have to inform patients that 3D™ exams add an incremental radiation dose to the 2D exam. Previously, we had developed a script for our technologists to use to educate patients about 3D™ exams so the patient could decide if they wanted a 3D™ or 2D exam. This protocol added time to our procedure, and created some anxiety for patients; some patients declined the 3D™ exam specifically because of the increased radiation dose. Replacing the 2D scan with C-View software eliminates the concern about dose, which makes the technologists’ workflow a little easier as they don’t have to discuss the increased dose issue with patients.
- As a result of the shorter compression time, we need to retake fewer images caused by motion. Previously, when we performed 2D + 3D exams, we had a motion problem on a significant number of images due to the duration of the total exposure. This was seen mostly in 2D images, which were taken after the 3D™ scan. Often patients would think the exam was complete after the 3D™ exam and they would move and relax. So, there were a significant number of 2D images that had motion. This wasn’t easy to see on the technologist’s workstation so, at times, we had to call back some patients. One of the advantages of C-View software is the shorter exposure time. Because it is shorter, patients can stop their breathing for the 3.7-second duration of the exam, which reduces the potential for motion.

**Administrative Changes: Correct Reporting Codes**

The key administrative change we had with C-View software was updating the exam codes and ensuring we use the correct verbiage in the report to describe the views we took. We had to make sure that we had text that would populate the report with the C-View exam that would say, for example for a routine screen, CC and MLO 3D and synthesized 2D views. We had to do a little bit of work to develop the text to put into the structured report describing the images that we obtained.

## Conclusions

C-View software is performing as expected; it is an effective imaging tool that allows us to eliminate the 2D image and reduce the radiation dose to our patients. This has allowed us to expand our use of 3D™ imaging, as more patients who previously would have opted for the 2D exam due to anxiety about the additional radiation are now choosing the 3D™ exam. As a result, we have established 3D™ exams as our imaging protocol for all mammograms, except in cases where a patient's insurance will not cover the exam. As with any new imaging tool, there is a learning curve to become familiar with the images and gain confidence in interpretation. Our experience shows that careful planning and a step-by-step transition can help radiologists develop confidence quickly and minimize any increase in false-positive callbacks.

## References:

1. FDA PMA Number P080003 S001. <http://www.accessdata.fda.gov/scripts/cdrh/cfdocs/cfpma/pma.cfm>
2. Skaane P, Bandos A, Eben E, et al. "Two-View Digital Breast Tomosynthesis Screening with Synthetically Reconstructed Projection Images: Comparison with Digital Breast Tomosynthesis with Full-Field Digital Mammographic Images" *Radiology*. 2014 Jun; 271:3, 655-663. Epub 2014 Jan 24. Zuley M, Guo B, Catullo V, et al. "Comparison of Two-dimensional Synthesized Mammograms versus Original Digital Mammograms Alone and in Combination with Tomosynthesis Images." *Radiology*. 2014 Jun; 271(3): 664-71. Epub 2014 Jan 21.
3. Skaane P, Bandos A, Eben E, et al. "Two-View Digital Breast Tomosynthesis Screening with Synthetically Reconstructed Projection Images: Comparison with Digital Breast Tomosynthesis with Full-Field Digital Mammographic Images" *Radiology*. 2014 Jun; 271:3, 655-663. Epub 2014 Jan 24.
4. Zuley M, Guo B, Catullo V, et al. "Comparison of Two-dimensional Synthesized Mammograms versus Original Digital Mammograms Alone and in Combination with Tomosynthesis Images." *Radiology*. 2014 Jun; 271(3): 664-71. Epub 2014 Jan 21.
5. Ratanaprasatporn L, Chikarmane S, Gless C, "Strengths and Weaknesses of Synthetic Mammography in Screening" *Radio Graphics* 2017 37:7, 1913-1927

---

**Hologic, Inc.**  
250 Campus Drive  
Marlborough, MA 01752 USA  
Tel: +1.508.263.2900  
Sales: +1.781.999.7453  
Fax: +1.781.280.0668  
[www.hologic.com](http://www.hologic.com)

WP-00121 (1/18) ©2018 Hologic, Inc. Hologic, 3D, 3D Mammography, C-View, Dimensions and Selenia are trademarks and/or registered trademarks of Hologic, Inc., and/or its subsidiaries in the United States and/or other countries. All other trademarks, registered trademarks, and product names are the property of their respective owners. This information is intended for medical professionals in the U.S. and other markets and is not intended as a product solicitation or promotion where such activities are prohibited. Because Hologic materials are distributed through websites, eBroadcasts and tradeshow, it is not always possible to control where such materials appear. For specific information on what products are available for sale in a particular country, please contact your local Hologic representative or write to [womenshealth@hologic.com](mailto:womenshealth@hologic.com).